

Preliminary Report on the Effects of Propolis on Wound Healing in the Dental Pulp

Walter A. Bretz^a, D. J. Chiego, Jr.^b, M. C. Marcucci^c, I. Cunha^d, A. Custódio^d, L. G. Schneider^a

^a University of Pittsburgh, School of Dental Medicine, 3501 Terrace Street, Pittsburgh, PA 15261–1923, USA

^b University of Michigan, School of Dentistry, Ann Arbor, MI 48109, USA

^c Bandeirante University of São Paulo, Pharmacy and Biochemistry Department, São Paulo, SP 02071–013, Brazil

^d Universidade São Francisco, School of Pharmaceutical Sciences, Bragança Paulista, SP 12900–000, Brazil

Z. Naturforsch. **53c**, 1045–1048 (1998); received May 29/August 3, 1998

Propolis, Dental Pulp, Wound Healing, Antimicrobial

The purpose of this investigation was to determine the antimicrobial and healing potential of propolis on direct dental pulp exposures. This study used 25 adult male rats. Pulp exposures were performed and animals were allocated to propolis and calcium hydroxide (Ca(OH)₂) groups. Animals were killed on days 5, 7, 10, and 14. The teeth were routinely processed for histological evaluation. Non-parametric tests were employed to analyze the data. No significant differences were found between study groups on the wound healing of the dental pulp. Both substances were comparable in exhibiting normal reorganization of the pulp and no increased vascularity, and were equally efficacious in maintaining a low inflammatory and microbial cell population as well as in stimulating the formation of reparative dentin.

Introduction

Propolis is a resin-like compound extracted from plants by bees, which is added to the bee's salivary secretions in order to avoid bacterial contamination in the hive, and also to seal it. The composition of propolis is primarily resins, waxes, balsams, volatile oils and pollen (Guisalberti *et al.*, 1978). The chemical composition of propolis is complex. Those include alcohols, aldehydes, aliphatic acids and esters, amino acids, aromatic acids and esters, flavanones, ketones and sugars, among others (Marcucci, 1995). These compounds may confer biological properties to propolis that remain not entirely understood.

It has been further demonstrated that cinnamic acid, chrysin and cinnamic acid ethylester are characteristic components of propolis which possess bacterial inhibitory properties against bacteria that cause dental caries (Ikeno *et al.*, 1991).

The therapeutic use of propolis in dentistry has been looked at in recent years: 1) as an antimicrobial in the treatment of periodontal diseases and dental caries (Ikeno *et al.*, 1991; Neumann *et al.*, 1986); 2) in the treatment of pulpal infections (Gafar *et al.*, 1986); 3) as a tissue repairing agent in wound healing after surgical procedures (Magro Filho and Carvalho, 1990; Magro Filho and Carvalho, 1994).

The purpose of this investigation was to determine the healing properties of propolis as a direct dental pulp capping agent in order to assess the effects of this substance on the regenerative process of the pulp.

Material and Methods

This study used 25, 250 g adult male rats (*Wistar*, Kalamazoo, Michigan, USA). A class V cavity preparation was performed on the mesiobuccal cusp of the first maxillary molar of each animal. Therefore, the tooth was the unit of analysis. We started the study with a larger number of rats than 25. For reasons beyond our control some rats were deceased. Similarly, teeth which had lost the com-

Reprint requests to Walter A. Bretz.

Fax: 412–3837796.

E-mail: Wab2+@pitt.edu

0939–5075/98/1100–1045 \$ 06.00 © 1998 Verlag der Zeitschrift für Naturforschung, Tübingen · www.znaturforsch.com D



Dieses Werk wurde im Jahr 2013 vom Verlag Zeitschrift für Naturforschung in Zusammenarbeit mit der Max-Planck-Gesellschaft zur Förderung der Wissenschaften e.V. digitalisiert und unter folgender Lizenz veröffentlicht: Creative Commons Namensnennung-Keine Bearbeitung 3.0 Deutschland Lizenz.

Zum 01.01.2015 ist eine Anpassung der Lizenzbedingungen (Entfall der Creative Commons Lizenzbedingung „Keine Bearbeitung“) beabsichtigt, um eine Nachnutzung auch im Rahmen zukünftiger wissenschaftlicher Nutzungsformen zu ermöglichen.

This work has been digitalized and published in 2013 by Verlag Zeitschrift für Naturforschung in cooperation with the Max Planck Society for the Advancement of Science under a Creative Commons Attribution-NoDerivs 3.0 Germany License.

On 01.01.2015 it is planned to change the License Conditions (the removal of the Creative Commons License condition “no derivative works”). This is to allow reuse in the area of future scientific usage.

posite filling material were excluded from the study accounting for the uneven number of experimental units observed in both groups throughout the study period.

The propolis used in this investigation was obtained from the Southeast region of Brazil (Volta Redonda, Rio de Janeiro, Brazil). The plant source was mainly *eucalyptus*.

Propolis was initially made up as a 20% solution (20 g triturated in 100 ml of 100% ethyl alcohol) and left overnight to allow for the propolis to be extracted. The solution was filtered using number 1 filter paper, placed in a rotary evaporator at room temperature until a thick paste was formed weighing approximately 2 g.

A quarter round bur (0.06 mm in diameter) at low speed was used to penetrate the pulp chamber. After hemostasis was attained, approximately 0.5 mg of propolis was placed directly on the exposed dental pulp of twelve teeth randomly selected. Thirteen teeth had a hard set calcium hydroxide ($\text{Ca}(\text{OH})_2$) pulp capping material (Life, Sybron/Kerr, Romulus, Michigan, USA) placed on the exposed dental pulp and were used as positive controls. All teeth were subsequently filled with a direct restorative material (resin composite).

Animals were killed on days 5, 7, 10 and 14. The maxillary molars were removed, placed in 4% neutral buffered formalin for 24 hours, and decal-

cified in 0.5M EDTA. The teeth were routinely processed for histological evaluation, embedded in paraffin and sectioned at 5 micrometers. Tissue sections were stained with three different staining procedures: 1) hematoxylin and eosin; 2) Preece modified bacterial staining; and 3) Preston's bacterial stain, and observed using a light microscope and attached digitizing table by an individual who was unaware of group origin, i.e., propolis vs $\text{Ca}(\text{OH})_2$. Evaluation criteria were the same as used by Heys *et al.* (1981). The parameters evaluated were the presence of fibroblasts, the pulpal response, presence of inflammatory cells, absence of microorganisms, organization of blood supply and hard tissue response.

Non-parametric *t*-tests were employed to analyze differences between treatment groups.

Results and Discussion

There were no significant differences between propolis and $\text{Ca}(\text{OH})_2$ with regards to pulpal and tooth responses (Table I). After 5 days, propolis was superior to $\text{Ca}(\text{OH})_2$ in terms of no initial inflammatory reaction and presence of fibroblasts, no bacterial contamination of the pulp and formation of reparative dentin. $\text{Ca}(\text{OH})_2$ was superior to propolis in demonstrating coronal responses only. Both substances were compa-

Table I. Effects of Propolis and $\text{Ca}(\text{OH})_2$ on pulp and tooth repairing properties after 5, 7, 10 and 14 days.

Histological Parameters	5 days		7 days		10 days		14 days	
	P	C	P	C	P	C	P	C
Fibroblasts present	2/2*	2/3	4/4	5/6	2/2	2/2	3/4	2/2
Pulpal Response coronal	1/2	3/3	4/4	6/6	2/2	2/2	2/4	1/2
Few to No PMN's	2/2	2/3	4/4	3/6	1/2	0/2	3/4	2/2
Microorganisms absent	2/2	2/3	4/4	3/6	2/2	1/2	3/4	2/2
Normal Pulp reorganization	2/2	3/3	4/4	6/6	2/2	0/2	3/4	0/2
Organized Blood supply	2/2	3/3	4/4	1/6	1/2	0/2	3/4	2/2
Reparative dentin/osteodentin/cementum	2/2	2/3	0/4	3/6	2/2	2/2	4/4	2/2

PMN, Leukocyte polymorphonuclear.

P, propolis.

C, $\text{Ca}(\text{OH})_2$.

* Number of events/total number of observations.

able in exhibiting normal reorganization of the pulp and no increased vascularity. There was a tendency for propolis to be superior or comparable to $\text{Ca}(\text{OH})_2$ in the majority of the parameters studied after 7 days. Similar responses were observed after 10 days. Fourteen-day responses indicated that $\text{Ca}(\text{OH})_2$ was slightly superior to propolis but not significantly, in maintaining a low inflammatory and microbial cell population but comparable to propolis with regards to bridge formation and reorganization of soft tissue.

Propolis may be used in several areas of specialization in dentistry, i.e., periodontics, endodontics, cariology and oral surgery. Our preliminary observations indicated that propolis was comparable and at times superior to $\text{Ca}(\text{OH})_2$, an often used pulp capping agent, in the reparative process of the pulp and tooth in the rat model. Propolis clearly exhibited antimicrobial and anti-inflammatory properties with dentinal

bridge formation (Fig. 1). There have been attempts to use antibiotics plus $\text{Ca}(\text{OH})_2$ to enhance the success rate of dentinal bridge formation (Ulmansky and Sela, 1971; Gardner *et al.*, 1971). Results from these studies imply that the effectiveness of this approach is very high. In this manner, propolis could be further tested in combination with pulp capping agents.

The effects of propolis on cariogenic organisms and on dental caries in rats was studied by Ikeno *et al.* (1991). Propolis had antimicrobial activity against cariogenic organisms and the occurrence of dental caries was significantly less in rats of the group given propolis. Acceleration of tissue repair and antimicrobial properties have also been attributed to propolis in the control of periodontal diseases and in the post operative management of oral surgery patients (Magro Filho and Carvalho, 1990; Silveira *et al.*, 1988).

Collectively, our results and the body of evidence suggesting wound healing and antimicro-

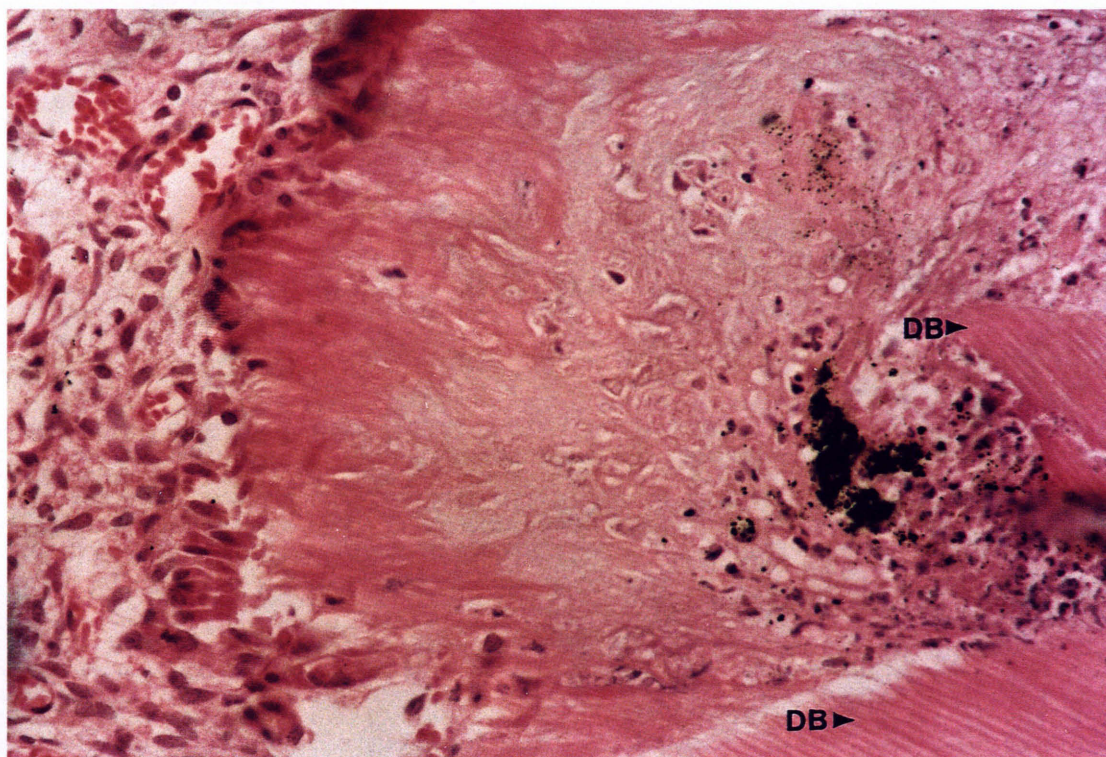


Fig. 1. DB- Dentinal bridge; Photomicrograph demonstrating the formation of a dentin bridge by replacement odontoblasts 14 days after an exposure and direct pulp capping with propolis. Hematoxylin and eosin. Orig. Mag.X125.

bial properties of propolis may warrant further investigations on the use of propolis in the treatment/control of dental and oral diseases.

Acknowledgments

We acknowledge the technical and editorial assistance of Dr. Kristen Johnson and Marion Brockie. This work was supported in part by a grant from FAPESP #95/9306-5 (Brazilian Agency).

- Gafar M., Sacalus A., David N. and David. E. (1986), Treatment of simple pulp gangrene with the apitherapy product propolis. *Stomatologie* **33**, 115–117.
- Gardner D. C., Mitchell D. F. and McDonald R. E. (1971), Treatment of pulps of monkeys with Vancomycin and Calcium Hydroxide. *J. Dent. Res.* **50**, 1273–1277.
- Ghisalberti E. L. (1979), Propolis: a review. *Bee World* **60**, 59–84.
- Heys D. R., Cox C. F., Heys R. J. and Avery J. K. (1981), Histological considerations of direct pulp capping agents. *J. Dent. Res.* **60**, 1371–1379.
- Ikeno K., Ikeno T. and Miyazawa C. (1991), Effects of propolis on dental caries in rats. *Caries Res.* **25**, 347–351.
- Magro Filho O. and Carvalho A. C. P. (1990), Application of propolis to dental sockets and skin wounds. *J. Nihon Univ. Sch. Dent.* **32**, 4–13.
- Magro Filho O. and Carvalho A. C. P. (1994), Topical effect of propolis in the repair of sulcoplasties by the modified kazanjian technique. *J. Nihon Univ. Sch. Dent.* **36**, 102–111.
- Marcucci M. C. (1995), Propolis: chemical composition, biological properties and therapeutic activity. *Apidologie* **26**, 83–99.
- Neumann D., Gotze G. and Binus W. (1989), Klinische Studien zur Untersuchung der Plaque- und Gingivitis Hemmung durch Propolis. *Stomatol. DDR* **36**, 677–681.
- Silveira G. M., Godoy A. G., Torriente R. O., Ortiz M. C. P. and Cuellar M. A. F. (1988), Estudio preliminar sobre los efectos del propolis en el tratamiento de la gingivitis crónica y de las úlceras bucales. *Rev. Cubana Estomatol.* **25**, 36–44.
- Ulmansky M. and Sela J. (1971), Response of pulpotomy wound in normal human teeth to successively applied Ledermix and Calxyl. *Arch. Oral Biol.* **16**, 1393–1398.